

Treatment of Bankart Lesions in Traumatic Anterior Instability of the Shoulder: A Randomized Controlled Trial Comparing Arthroscopy and Open Techniques

Nicola Archetti Netto, M.D., Ph.D., Marcel Jun Sugawara Tamaoki, M.D., Ph.D.,
Mario Lenza, M.D., Ph.D., João Baptista Gomes dos Santos, M.D., Ph.D.,
Marcelo Hide Matsumoto, M.D., Ph.D., Flavio Faloppa, M.D., Ph.D., and
João Carlos Belloti, M.D., Ph.D.

Purpose: The objective of this study was to compare the functional assessments of arthroscopy and open repair for treating Bankart lesion in traumatic anterior shoulder instability. **Methods:** Fifty adult patients, aged less than 40 years, with traumatic anterior shoulder instability and the presence of an isolated Bankart lesion confirmed by diagnostic arthroscopy were included in the study. They were randomly assigned to receive open or arthroscopic treatment of an isolated Bankart lesion. In all cases of both groups, the lesion was repaired with metallic suture anchors. The primary outcomes included the Disabilities of the Arm, Shoulder and Hand (DASH) questionnaire. **Results:** After a mean follow-up period of 37.5 months, 42 patients were evaluated. On the DASH scale, there was a statistically significant difference favorable to the patients treated with the arthroscopic technique, but without clinical relevance. There was no difference in the assessments by University of California, Los Angeles and Rowe scales. There was no statistically significant difference regarding complications and failures, as well as range of motion, for the 2 techniques. **Conclusions:** On the basis of this study, the open and arthroscopic techniques were effective in the treatment of traumatic anterior shoulder instability. The arthroscopic technique showed a lower index of functional limitation of the upper limb, as assessed by the DASH questionnaire; this, however, was not clinically relevant. **Level of Evidence:** Level II, randomized controlled trial.

The treatment of traumatic anterior shoulder instability associated with Bankart lesion remains controversial in orthopaedics. The anatomic repair of the capsulolabral complex of the glenoid has become the gold-standard treatment for the referred disease since the

findings obtained by Bankart in 1938.¹⁻⁴ In the 1980s, the treatment of Bankart lesion was the minimally invasive approach of arthroscopy. The main advantages of this method are less damage to the soft tissues, shorter duration of surgery, shorter hospital stay, and low postoperative complication rate, and some studies report lower postoperative restriction of the range of motion.⁵⁻⁷ The main criticism of this method concerns the significant recurrence rate of shoulder dislocations compared with the open technique.⁸⁻¹¹ Recently, a systematic review concluded that there was a lower recurrence rate of shoulder dislocation in favor of arthroscopic technique.¹² However, there are few comparative studies with an adequate design analysis method to corroborate this conclusion.¹² The purpose of this prospective and randomized study was to compare the outcomes of arthroscopy and open repair for

From the Division of Hand and Upper Limb Surgery, Department of Orthopedics and Trauma, Universidade Federal de São Paulo—Escola Paulista de Medicina, São Paulo, Brazil.

The authors report that they have no conflicts of interest in the authorship and publication of this article.

Received May 2, 2011; accepted November 22, 2011.

Address correspondence to Marcel Jun Sugawara Tamaoki, M.D., Ph.D., Department for Orthopedic Surgery and Traumatology, Hospital São Paulo, Rua Borges Lagoa 786, 04038-001 São Paulo (SP), Brazil. E-mail: marceltamaoki@terra.com.br

*© 2012 by the Arthroscopy Association of North America
0749-8063/11273/\$36.00*

doi:10.1016/j.arthro.2011.11.032

traumatic anterior shoulder instability in a homogeneous group of patients, assessing postoperative function and recurrence.

Our hypothesis was that using the arthroscopic technique would result in more favorable Disabilities of the Arm, Shoulder and Hand (DASH) score assessment compared with the open technique.

METHODS

This randomized trial was conducted from November 2003 to December 2006 (ISRCTN22171602).

Inclusion criteria for the study group were (1) adult patients aged less than 40 years; (2) patients with more than 1 episode of shoulder traumatic dislocation, with at least 2 anteroposterior- and lateral-view radiographs showing anterior shoulder dislocation; (3) clinical history of traumatic anterior instability of the shoulder, with positive apprehension or relocation tests, as well as an asymptomatic contralateral shoulder; and (4) arthroscopic confirmation of Bankart lesion. The exclusion criteria were (1) patients with multidirectional and/or voluntary instability; (2) patients with convulsive disorders, collagen diseases, previous shoulder surgeries, and any other conditions that might affect the mobility of the joint; (3) patients with bony glenoid lesion confirmed by radiographic examination; (4) arthroscopic visualization of an “engaging Hill-Sachs lesion” and/or inverted-pear glenoid¹³; (5) patients with SLAP lesion types II, III, and IV, according to the classification of Snyder et al.,¹⁴ and/or partial- or full-thickness rotator cuff tears, confirmed by arthroscopy; and (6) patients who refused to sign the consent form.

Sample size estimations were performed before the recruitment of the patients. The main variable used was the DASH questionnaire.^{15,16} Type I error was pre-established as 5% (95% confidence interval) and type II error as 20% (power of 80%) with a population standard deviation of 18%.

To calculate our sample size, we used the following mathematic method:

$$n = [(Z\alpha/2 + Z\beta)^2 \cdot \sigma^2] / \epsilon^2$$

where $Z\alpha/2$ is the critical value α from the standard normal distribution with upper tail, $Z\alpha$ is the critical value α from the standard normal distribution, σ is the population standard deviation, and ϵ is the difference in the DASH questionnaire, which was assumed to be clinically relevant.

The values $Z\alpha/2$ (type I error) and $Z\alpha$ (type II error) were obtained by standard normal distribution tables.

Thus, assuming the values described in the text, we have anticipated that 25.4 participants would be required in each group.

After signing informed consent forms, the patients were sequentially included and randomly allocated to 1 of the surgical procedures, by use of a computer-generated randomization schedule—Research Randomizer computer software, developed by Geoffrey C. Urbaniak and Scott Plous. After the verification of the arthroscopic inclusion criterion, the randomization to either arthroscopic or open technique was made by individuals not directly related to the study using a sequentially numbered, opaque, sealed envelope.

All the patients underwent general anesthesia associated with brachial plexus block and attended the outpatient clinic during the postoperative period. The surgical interventions were performed by 4 surgeons with experience in both techniques, according to the same pre-established protocol. At first, the patients underwent diagnostic arthroscopy in the beach-chair position, and only after verification of the inclusion and exclusion criteria were the envelopes with the description of the randomized procedure (open or arthroscopic technique) opened.

Treatment of Bankart Lesion by Open Technique

The surgical technique was the modified Bankart procedure described by Matsen et al.¹⁷ (Fig 1). The patients were placed in the beach-chair position, and surgery was performed with a deltopectoral incision with subscapularis detachment. Repair of the Bankart lesion was performed with $4 \times 13 \times 2$ -mm threaded metal anchors (Hexagon Brasil, Campinas, Brazil) loaded with No. 2 Ethibond (Ethicon, Somerville, NJ) from 5 mm of the edge of the glenoid joint. The capsule and the subscapularis tendon were sutured by a side-to-side repair with No. 2 Ethibond, the superficial layers were then closed, and no drainage was used. In the immediate postoperative period, all patients were advised to wear a sling for total restriction of external rotation and abduction.

Repair of Bankart Lesion by Arthroscopy

Bankart lesion repair was performed with a procedure described by Snyder,¹⁸ with the patient in the lateral decubitus position (repositioned after diagnostic arthroscopy in beach-chair position) (Fig 2). An arthroscopic suture passer (Suture Punch or Spectrum; Linvatec, Largo, FL) was used to suture the labrum around the edge of the glenoid cavity with $4 \times 13 \times$

FIGURE 1. (A and B) Open repair of right shoulder. (A, anchor position; C, capsule; G, glenoid; SA, articular surface; U, humerus.)

2-mm metal anchors (Hexagon Brasil) loaded with No. 2 Ethibond from 5 mm of the edge of the glenoid cavity. All patients were advised to wear a sling for total restriction of external rotation and abduction.

For both techniques, the number of anchors used for each repair was decided by each surgeon during the intraoperative procedure.

Postoperative Period

On discharge, all the patients were given nonsteroidal anti-inflammatory drugs (meloxicam, 15 mg/d) for 5 days and painkillers (paracetamol, 750 to 2,250 mg/d) where necessary for 7 days. The patients attended the outpatient clinic in the first week for banding

and in the second week for stitch removal. The other appointments occurred in the fourth and eighth weeks and, afterward, on a monthly basis until the end of the follow-up period.

All the patients were rehabilitated according to the same protocol. In the first 7 postoperative days, sling use was maintained continuously and the sling was only removed for elbow flexion-extension. From the seventh day on, the patients were advised to maintain discontinuous immobilization for 3 more weeks, only removing the sling for active and passive elbow movement and passive shoulder movement up to 0° of external rotation and 90° of abduction in the scapular plane, 3 times a day. In the fourth week, immobiliza-

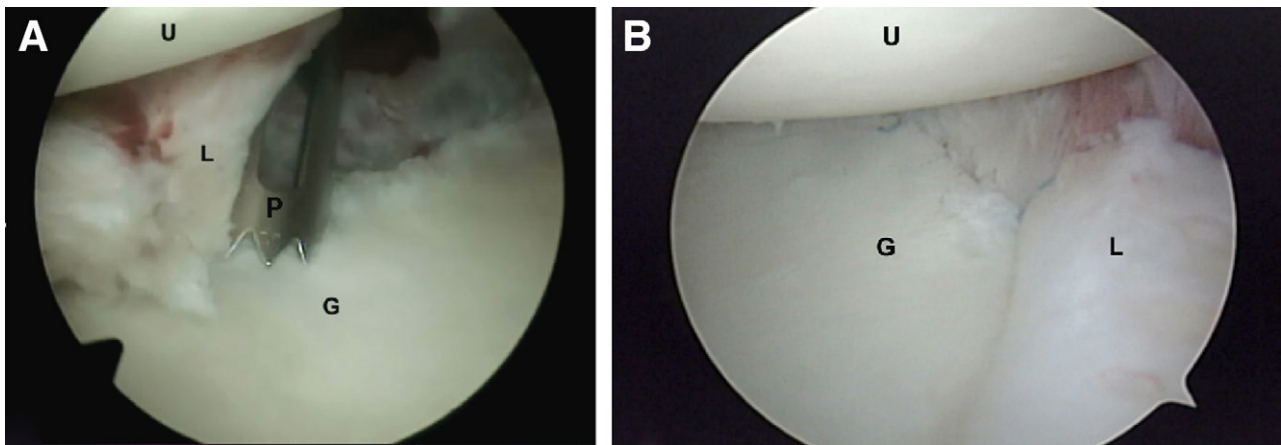


FIGURE 2. (A and B) Arthroscopic repair of left shoulder, posterior portal view. (G, glenoid; L, labrum [in A]/reattached labrum [in B]; P, guide of anchor; U, humerus.)

tion was eliminated, and progressive range of movement was gained in all participants. The patients were discharged from physiotherapy 16 weeks later and were able to participate in sporting activities 24 weeks after surgery.

All the participants were examined from 2007 to 2008 by physicians (residents under supervision of board-certified shoulder surgeons) not directly involved in the study. The primary outcome assessed was the DASH questionnaire validated and translated into Portuguese^{15,16}; the final score of the DASH questionnaire was turned into a percentage by use of the following formula: $\text{Scoring} = [\text{Sum of answers } n/n - 1] \times 25$, where n is the number of complete answers. The 2 optional modules were not measured. The value obtained was directly proportional to the percentage of impairment of the limb function.

The University of California, Los Angeles (UCLA) scale¹⁹ and the Rowe scale² were also evaluated as secondary outcomes.

Two evaluators measured the bilateral range of movement using the Carci universal goniometer (Carci, São Paulo, Brazil). Elevation and active external rotation, both in the scapular plane, were measured by comparison of preoperative and postoperative descriptive variables. Internal active rotation was assessed before and after surgery by use of part of the Constant functional assessment scale.²⁰ Radiographic examination was performed in the first postoperative week and during the final assessment, including anteroposterior and axillary views and a lateral view of the scapula.

Statistical Method

The variables were summarized by study group and represented by the pertinent descriptive statistics: mean, standard deviation, median, minimum and maximum values, or absolute and relative frequencies (percents). The surgery groups were compared regarding the qualitative variables by use of the χ^2 test or Fisher exact test. The Student t test or Mann-Whitney test was used in the comparison between surgery groups regarding quantitative variables, according to the presence of normal distribution in the assessed variables. The Wilcoxon test was used in the comparison between preoperative and postoperative measures for each side within each group. The paired t test or Wilcoxon test was used in the comparison of the affected and contralateral sides regarding the quantitative variables, according to the occurrence of normal distribution in the variations between the sides. This

analysis was performed in the total sample and for each surgery group separately. A significance level of .05 ($\alpha = 5\%$) was used, and the SPSS statistical program for Windows (version 15.0; SPSS, Chicago, IL) was run in all the analyses.

All recurrences that required additional interventions not included within the protocol were considered complications. A need for further intervention or a change in the initial randomized treatment was considered a failure. Patients for whom treatment has failed, regardless of the reason, were followed up, and the results were included in the original group, according to the intention-to-treat principle.

RESULTS

Fifty-six patients who fulfilled the inclusion criteria were considered eligible for the study. Of these, after the diagnostic arthroscopy, 6 were excluded: 3 had SLAP lesion (1 type II and 2 type III), 2 had glenoid bone defect, and 1 had partial-thickness rotator cuff tear (Fig 3). We randomized 50 patients for the 2 intervention methods, of whom 42 completed the final follow-up (25 in open technique group and 17 in arthroscopy group). There was no significant difference in demographic data between the 2 groups (Table 1). Of the 8 patients (16%) who were not assessed, 2 died of causes unrelated to the intervention and the other 6 quit the study before the first month of follow-up without any complications. The mean follow-up period was 37.5 months, ranging from 20 to 56 months (Fig 3).

Comparison between groups showed a statistically significant difference in favor of the arthroscopy group when we assessed the primary outcome, DASH questionnaire ($P = .031$), with a mean difference of 1.57 points (Tables 1 and 2).

No significant differences between groups were seen in the secondary outcomes overall. No statistically significant differences were found between the techniques for the UCLA and Rowe scores ($P > .999$) (Table 2). Moreover, no statistically significant differences were found between the techniques for the assessments of shoulder range of motion of the affected side in the preoperative and postoperative periods (Table 3).

The 2 study groups did not differ significantly with respect to the number of anchors used during the surgical interventions (Table 4).

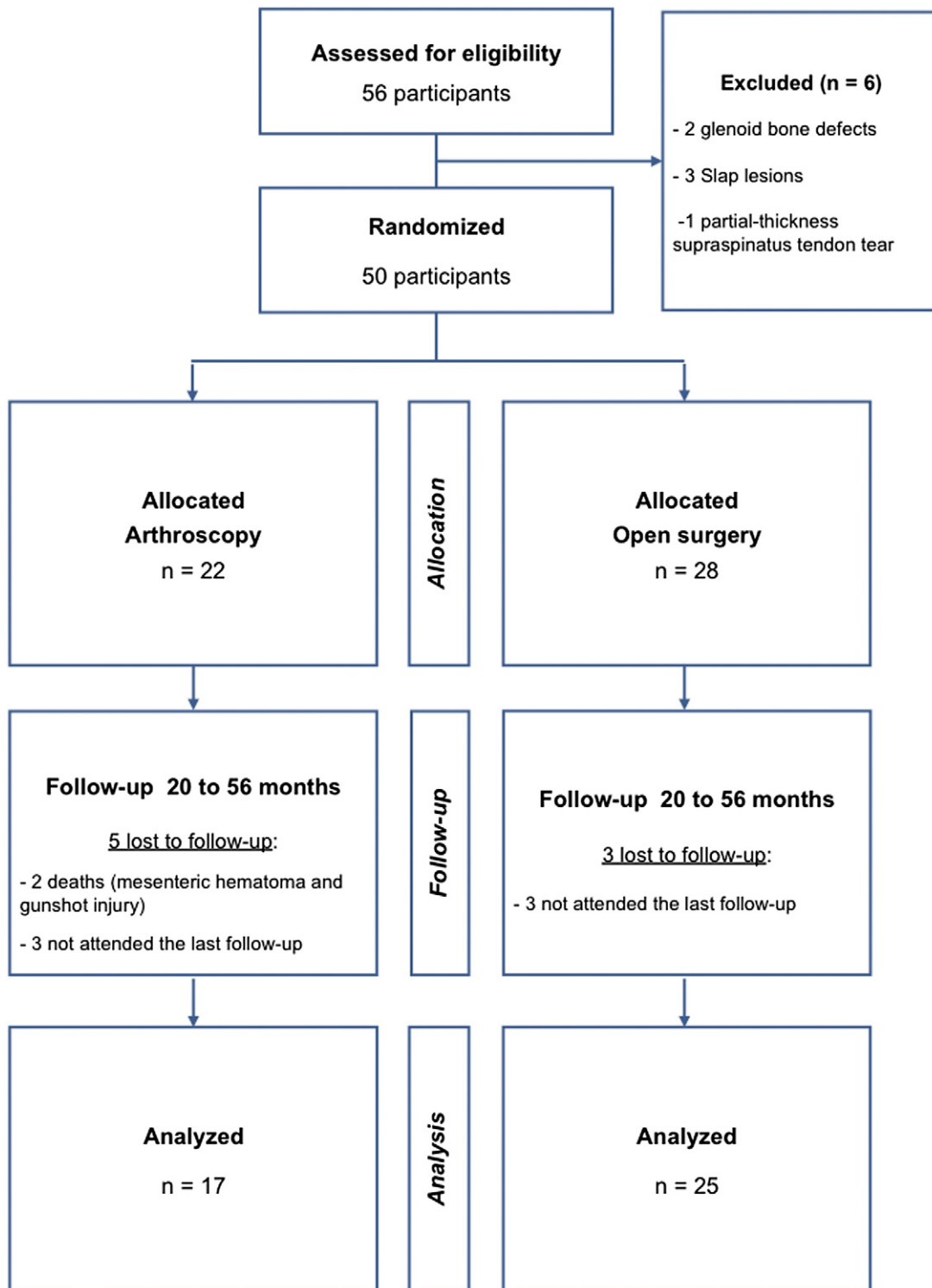


FIGURE 3. Enrollment, assigned intervention, and follow-up.

TABLE 1. Demographic Data

Variable	Open (n = 25)	Arthroscopic (n = 17)	Comparison
Mean age (SD) (yr)	30.8 (5.6)	27.5 (5.4)	$P = .065$
Right side (%)	12 (48%)	9 (52.9%)	$P = .753$
Arm dominance (%)	22 (88.0%)	16 (94.1%)	$P = .635$
Mean time from first dislocation to surgery (SD) (mo)	62.9 (55.0)	45.7 (41.8)	$P = .424$
Mean no. of episodes of dislocation (SD)	16.3 (12.1)	10.8 (6.4)	$P = .160$
Male gender (%)	21 (84.0)	16 (94)	$P = .632$

Adverse Events

No complications were associated with the use of the metal anchors, such as malposition, loosening, or migration of the implants. One patient in the open group presented with wound superficial infection, which demanded a 4-week treatment with antibiotics, but there was no need for a new surgical intervention or treatment change (patient 40).

There were 2 cases of failure in the arthroscopic group (patients 12 and 13) and none in the open technique group ($P = .158$). These 2 patients reported symptoms of anterior instability with a new traumatic episode of shoulder dislocation that required additional surgical intervention, with an open technique.

DISCUSSION

Bankart surgery is the standard of excellence for the repair of the labrum and capsule in the treatment of anterior shoulder instability.^{9,11,21-23} On the basis of revisions of controlled clinical trials, there is no conclusive evidence to determine which technique is more effective in the surgical treatment of Bankart lesion: open or arthroscopic procedure.^{12,24} The main criticism of the arthroscopic method concerns the significant recurrence rate of shoulder dislocations compared with the open technique. However, this finding was based on comparisons of the open technique using anchors versus the arthroscopic treatment using transglenoid suture fixation or other fixation techniques ("tacks") in studies with different method designs with a reduced number of patients.

Our study was aimed to assess the effectiveness of the open and arthroscopic methods in the treatment of Bankart lesion in traumatic anterior shoulder instabil-

ity. The calculation of the sample size was based on the main outcome, which was the assessment of upper limb disability with the DASH scale, including a total of 50 patients. There are 2 studies with a similar design comparing both procedures, which included 60 and 64 patients.^{7,25}

Randomization was performed with computer software, and the results were kept in opaque and sealed envelopes, which were only opened at the moment of the main intervention. As for our sampling group, we observed that the inclusion and exclusion criteria allowed the allocation of 2 homogeneous groups that had only isolated Bankart lesions. However, in the study of Bottoni et al.,²⁵ the criteria used were not adequate, resulting in a heterogeneous sample, which may have influenced the results.

Diagnostic arthroscopy was used as an inclusion criterion because it is the gold standard for the diagnosis of intra-articular injury. Therefore we ensured the presence of isolated Bankart lesions, as has been performed in the study of Fabbriani et al.⁷ but not in the study of Bottoni et al.,²⁵ who used preoperative magnetic resonance imaging in all patients, concluding that sensitivity and specificity are not entirely reliable.

We have selected isolated Bankart lesions that are not associated with glenoid bone defect and/or engaging Hill-Sachs lesion, because both lesions have a negative impact on the outcome of surgical treatment of Bankart lesions, increasing failure rates.¹³ These 2 exclusion criteria adopted in our study were not used in the study of Bottoni et al.,²⁵ and Fabbriani et al.⁷ only excluded patients with glenoid bone defect, which may have influenced their findings. SLAP lesions and rotator cuff tears were also excluded in our

TABLE 2. DASH, UCLA, and Rowe Scores

Endpoint	Technique		Comparison
	Open (n = 25)	Arthroscopic (n = 17)	
DASH			$P = .031$
Mean (SD)	4.22 (5.8)	2.65 (7.3)	
Median	1.66	0	
Range	0-20.83	0-24.16	
UCLA			
Good/excellent (%)	23 (92.0)	16 (94.1)	
Fair/poor (%)	2 (8.0)	1 (5.9)	$P > .999$
Rowe			
Excellent (%)	20 (80)	13 (76.5)	
Good (%)	5 (20)	1 (5.9)	
Fair (%)	0	3 (17.6)	$P > .999$

TABLE 3. *Shoulder Range of Motion of Affected Side*

Variable	Assessment			Comparison
	Arc of Movement Before Intervention	Arc of Movement After Intervention	Difference	
Elevation (°)				
Open technique	167.6 (17.0)	165.8 (19.7)	-1.8 (26.4)	<i>P</i> = .936
Arthroscopic technique	169.0 (21.7)	174.8 (8.2)	5.8 (17.2)	<i>P</i> = .310
Comparison			<i>P</i> = .673	
External rotation (°)				
Open technique	63.2 (13.9)	59.9 (14.6)	-3.3 (11.9)	<i>P</i> = .071
Arthroscopic technique	74.5 (11.4)	70.8 (17.2)	-3.6 (14.4)	<i>P</i> = .155
Comparison			<i>P</i> = .969	
Internal rotation (°)				
Open technique	8.9 (2.1)	8.8 (2.0)	0.1 (2.3)	<i>P</i> = .880
Arthroscopic technique	8.7 (1.9)	8.8 (1.7)	-0.1 (1.8)	<i>P</i> = .860
Comparison			<i>P</i> = .970	

NOTE. Data are presented as mean/standard deviation.

study, because we did not want to consider any additional known factor that might cause pain or restriction of movement in the postoperative period. Fabbri-ciani et al. also excluded SLAP and rotator cuff lesions, whereas Bottoni et al. did not describe these criteria.

The postoperative period is an important factor related to recurrence of instability. According to the literature, the period suggested for the assessment of instability recurrence is approximately 2 years. In our study the mean follow-up period was 37 months, greater than the follow-up period in the studies of Fabbri-ciani et al.⁷ and Bottoni et al.²⁵ of 24 months and 29 months, respectively.

Regarding the surgical techniques discussed in our study, the open technique was the modified Bankart procedure described by Matsen et al.,¹⁷ the same one used in the study of Fabbri-ciani et al.⁷ However, Bottoni et al.²⁵ performed capsuloplasty as described by Neer and Foster²⁶ in association with Bankart repair, which may generate an additional mechanism of shoulder stabilization or even postoperative restriction of movements. In our study we used the arthroscopic technique described by Snyder,¹⁸ which is similar to the open technique, because it promotes the reattachment of the labrum in the edge of the glenoid without causing excessive tightening of the joint capsule, as in the study of Fabbri-ciani et al. We believe that this surgical approach can be compared with the open Bankart technique used in our study. Bottoni et al. used the arthroscopic procedure described by Bottoni and Arciero,²⁷ stress-

ing the tightening of the capsule associated with suture through the glenoid labrum.

The DASH scale, our primary outcome, is described as a superior psychometric assessment tool compared with other scales such as the American Shoulder and Elbow Surgeons assessment, Shoulder Pain and Disability Index, and Simple Shoulder Test.²⁸ Although arthroscopy showed better results in the endpoint DASH (*P* = .031), in absolute values, the difference was less than 10 points, which means not clinically relevant.²⁸ This outcome cannot be compared with similar results in the literature, because there was no analysis of the DASH score in the studies of Fabbri-ciani et al. and Bottoni et al.

Regarding the assessments using the UCLA and Rowe shoulder scores, there was no significant difference between the open and arthroscopic groups. Concerning the results of functional assessments in other studies, Bottoni et al.²⁵ used the Single Assessment Numeric Evaluation, UCLA, and Simple Shoulder Test scales to perform the functional comparison of the arthroscopic and open groups, as well as the Western Ontario Shoulder Instability scale

TABLE 4. *Number of Suture Anchors*

No. of Anchors (%)	Open	Arthroscopic	Comparison
1	1 (4.0%)	2 (11.8%)	<i>P</i> = .375
2	17 (68.0%)	7 (41.2%)	
3	7 (28.0%)	7 (41.2%)	
4	0 (0.0%)	1 (5.9%)	

for assessing shoulder stability, and they found no statistically significant differences between the groups. Fabbriani et al.⁷ used the Constant shoulder score for functional assessment and Rowe standard rating scale.

We assessed range of motion as a secondary outcome. For the evaluation of internal rotation, we chose the criteria of the Constant shoulder score and assigned a numeric value to the position arm.²⁰ Concerning the evaluation of this variable, we used examiners blinded to the groups to reduce bias, as in the study by Bottoni et al.²⁵ Our results did not show significant differences between the scapular plane abduction, internal rotation, and external rotation, which is consistent with the findings of Bottoni et al. Nevertheless, Fabbriani et al.⁷ found statistically significant values favorable to the arthroscopic technique using the Constant shoulder score.

Regarding the complications related to surgical techniques, 1 patient in the open group had a surgical wound infection and needed antibiotic therapy. No patient in the arthroscopic group had any complication. The study of Fabbriani et al.⁷ reported no complication in any of the groups. On the other hand, Bottoni et al.²⁵ reported a late complication of the open technique, which led to rupture of the subscapularis tendon. Other studies, such as that of Green and Christensen,⁶ reported a greater number of complications with open Bankart surgery compared with the arthroscopic procedure. No complication associated with the type of anchor was reported in our study. Likewise, Fabbriani et al. used metal anchors without any complication, and Bottoni et al. used bioabsorbable anchors without any complications. No differences in outcomes of interventions for treating shoulder instability were seen whether absorbable or nonabsorbable anchors were used.^{29,30} Regarding the number of anchors used, no difference was shown between the open and arthroscopic groups, a result similar to that found in the study of Bottoni et al.; this was not reported in the study of Fabbriani et al. Apparently, there is equal demand between the techniques.

Concerning failures, none was detected in the open technique; however, 2 anterior instability recurrences were observed in the arthroscopic group ($P = .158$). The 2 instability recurrences were associated with a new trauma with shoulder dislocation, in contact sports, with only 1 case of dislocation until the end of our follow-up. The profile of the activity of each patient is directly related to the recurrence because of the exposure to the risk of further trauma. There is

controversy in the literature regarding the indications for the arthroscopic technique in the treatment of patients who play contact sports. However, we believe that postsurgical recurrence in sports is because of the occurrence of a new trauma, which may cause dislocation in any of the shoulders, whether operated on or not.¹³

Fabbriani et al.⁷ and Bottoni et al.²⁵ described no significant difference in instability recurrence between open and arthroscopic techniques.

We included all the standards of detachment of the glenoid labrum because of the various episodes of dislocations and also because of the long period between the first dislocation and the surgical intervention, which has made it difficult to perform the standard diagnosis of these lesions. Habermeyer et al.³¹ assessed the evolution of intra-articular lesion in the instability of the shoulder using arthroscopy. They concluded that relapses have progressively damaged the stabilizing structures. However, they did not correlate such recurrent events with Bankart variants, such as the subperiosteal detachment of the glenoid labrum (anterior labroligamentous periosteal sleeve avulsion). Although some articles have described higher failure-of-treatment rates in patients with anterior labroligamentous periosteal sleeve avulsion variation, controlled prospective studies are needed, because various factors are involved in these failures.³²

One weakness of our study was sampling loss in the postoperative follow-up period of 3 patients in the open group and 5 patients in the arthroscopic group. Of the 5 non-evaluated patients in the arthroscopic group, 2 died of causes unrelated to the treatment (1 died of mesenteric vessel thrombosis at 16 months postoperatively and 1 died of a gunshot wound) and 3 did not attend the final evaluation appointment, which may have affected our results because there has been a more significant sampling loss in the arthroscopic group (Fig 3).

Our study had other sources of bias. First, the study design did not permit blinding of participants, surgeons, and outcome assessors; although failure of blinding can have a serious effect on study outcomes, we were unable to perform blinding. Second, 4 surgeons performed all surgical interventions; despite the fact that they are board-certified shoulder surgeons with more than 5 years' experience, this might be a cause of performance bias and recording. Third, this study was slightly underpowered. Finally, we also have reservations about the DASH score; although it may have been validated for use in a number of settings, this score may not be specific for use as an

outcome in shoulder instability, most likely because it refers to the whole upper limb.

CONCLUSIONS

On the basis of this study, the open and arthroscopic techniques were effective in the treatment of traumatic anterior shoulder instability. The arthroscopic technique showed a lower index of functional limitation of the upper limb, as assessed by the DASH questionnaire; this, however, was not clinically relevant.

REFERENCES

- Bankart ASB. The pathology and treatment of recurrent dislocation of the shoulder joint. *Br J Surg* 1938;26:23-29.
- Rowe CR, Patel D, Southmayd WW. The Bankart procedure: A long-term end-result study. *J Bone Joint Surg Am* 1978;60:1-16.
- Rosenberg BN, Richmond JC, Levine WN. Bankart repair for anterior instability of the shoulder. Long-term outcome. *J Bone Joint Surg Am* 1998;80:1083-1084.
- Pagnani MJ. Open capsular repair without bone block for recurrent anterior shoulder instability in patients with and without bony defects of the glenoid and/or humeral head. *Am J Sports Med* 2008;36:1805-1812.
- Wang C, Ghalambor N, Zarins B, Warner JP. Arthroscopic versus open Bankart repair: Analysis of patient subjective outcome and cost. *Arthroscopy* 2005;21:1219-1222.
- Green MR, Christensen KP. Arthroscopic versus open Bankart procedures: A comparison of early morbidity and complications. *Arthroscopy* 1993;9:371-374.
- Fabbriciani C, Milano G, Demontis A, Fadda S, Ziranu F, Mulas PD. Arthroscopic versus open treatment of Bankart lesion of the shoulder: A prospective randomized study. *Arthroscopy* 2004;20:456-462.
- Freedman KB, Smith AP, Romeo AA, Cole BJ, Bach BR Jr. Open Bankart repair versus arthroscopic repair with transglenoid sutures or bioabsorbable tacks for recurrent anterior instability of the shoulder: A meta-analysis. *Am J Sports Med* 2004;32:1520-1527.
- Mohtadi NG, Bitar IJ, Sasyniuk TM, Hollinshead RM, Harper WP. Arthroscopic versus open repair for traumatic anterior shoulder instability: A meta-analysis. *Arthroscopy* 2005;21:652-658.
- Hobby J, Griffin D, Boileau P. Is arthroscopic surgery for stabilisation of chronic shoulder instability as effective as open surgery? A systematic review and meta-analysis of 62 studies including 3044 arthroscopic operations. *J Bone Joint Surg Br* 2007;89:1188-1196.
- Lenters TR, Franta AK, Wolf FM, Leopold SS, Matsen FA III. Arthroscopic compared with open repairs for recurrent anterior shoulder instability. A systematic review and meta-analysis of the literature. *J Bone Joint Surg Am* 2007;89:244-254.
- Petrera M, Patella V, Patella S, Theodoropoulos J. A meta-analysis of open versus arthroscopic Bankart repair using suture anchors. *Knee Surg Sports Traumatol Arthrosc* 2010;18:1742-1747.
- Burkhart SS, De Beer F. Traumatic glenohumeral bone defects and their relationship to failure of arthroscopic Bankart repairs: Significance of the inverted-pear glenoid and the humeral engaging Hill-Sachs lesion. *Arthroscopy* 2000;16:677-694.
- Snyder SJ, Karzel RP, del Pizzo W, Ferkel RD, Friedman MJ. SLAP lesions of the shoulder. *Arthroscopy* 1990;6:274-279.
- Hudak PL, Amadio PC, Bombardier C. Development of an upper extremity outcome measure: The DASH (Disabilities of the Arm, Shoulder and Hand) [corrected]. The Upper Extremity Collaborative Group (UECG). *Am J Ind Med* 1996;29:602-608.
- Orfale AG, Araújo PM, Ferraz MB, Natour J. Translation into Brazilian Portuguese, cultural adaptation and evaluation of the reliability of the Disabilities of the Arm, Shoulder and Hand Questionnaire. *Braz J Med Biol Res* 2005;38:293-302.
- Matsen FA, Lippitt SB, Slides JA, Harryman DT. *Practical evaluation and management of the shoulder*. Ed 1. Philadelphia: Saunders, 1994.
- Snyder SJ. *Shoulder arthroscopy*. Ed 2. New York: McGraw-Hill, 1996.
- Oku EC, Andrade AP, Stadiniky SP, Carrera EF, Tellini GG. Tradução e adaptação cultural do Modified-University of California at Los Angeles Shoulder Rating Scale para a língua portuguesa. *Rev Bras Reumatol* 2006;46:246-252.
- Constant CR, Murley AHG. A clinical method of functional assessment of the shoulder. *Clin Orthop Relat Res* 1987;160-164.
- Guanche CA, Quick DC, Sodergren KM, Buss DD. Arthroscopic versus open reconstruction of the shoulder in patients with isolated Bankart lesions. *Am J Sports Med* 1996;24:144-148.
- Geiger DF, Hurley JA, Tovey JA, Rao JP. Results of arthroscopic versus open Bankart suture repair. *Clin Orthop Relat Res* 1997;111-117.
- Hubbell JD, Ahmad S, Bezenoff LS, Fond J, Petrone FA. Comparison of shoulder stabilization using arthroscopic transglenoid sutures versus open capsulolabral repairs: A 5-year minimum follow-up. *Am J Sports Med* 2004;32:650-654.
- Pulavarti RS, Symes TH, Rangan A. Surgical interventions for anterior shoulder instability in adults. *Cochrane Database Syst Rev* 2009;7:CD005077.
- Bottoni CR, Smith EL, Berkowitz MJ, Towle RB, Moore JH. Arthroscopic versus open shoulder stabilization for recurrent anterior instability: A prospective randomized clinical trial. *Am J Sports Med* 2006;34:1730-1737.
- Neer C, Foster C. Inferior capsular shift for involuntary inferior and multidirectional instability of the shoulder. *J Bone Joint Surg Am* 1980;62:897-908.
- Bottoni CR, Arciero RA. Arthroscopic repair of primary anterior dislocations of the shoulder. *Tech Shoulder Elbow Surg* 2001;2:2-16.
- Roy JS, Macdermid JC, Woodhouse LJ. Measuring shoulder function: A systematic review of four questionnaires. *Arthritis Rheum* 2009;61:623-632.
- Milano G, Grasso A, Santagada DA, et al. Comparison between metal and biodegradable suture anchors in arthroscopic treatment of traumatic anterior shoulder instability: A prospective randomized study. *Knee Sports Traumatol Arthrosc* 2010;18:1785-1791.
- Tan CK, Guisasola I, Machani B, et al. Arthroscopic stabilization of the shoulder: A prospective randomized study of absorbable versus nonabsorbable suture anchors. *Arthroscopy* 2006;22:716-720.
- Habermeyer P, Gleyze P, Rickert M. Evolution of lesions of the labrum-ligament complex in posttraumatic anterior shoulder instability: A prospective study. *J Shoulder Elbow Surg* 1999;8:66-74.
- Ozbaydar M, Elhassan B, Diller D, Massimini D, Higgins LD, Warner JJ. Results of arthroscopic capsulolabral repair: Bankart lesion versus anterior labroligamentous periosteal sleeve avulsion lesion. *Arthroscopy* 2008;24:1277-1283.